Fig. 1: The use of prehospital transcranial ultrasound to diagnose embolic strokes, performed by trained EMS personnel, could significantly improve stroke care (Photograph: AAMS/Mark Mennie)

Prehospital use of portable ultrasound for stroke diagnosis and treatment initiation

Author:
Thilo Hölscher
Director
Brain Ultrasound Research Laboratory (BURL)
University of California
San Diego

Despite all advancements in medical science, stroke remains the second common cause of death worldwide (1). There is an increasing number of stroke victims each year, independent of the cultural, the geographical or the socio-economic background (2). Stroke has been the most common cause of early invalidity worldwide for many years, contributing to the rapidly increasing costs for Medicare and long-term support. Similar to other ischemic diseases, such as myocardial infarction, the success of treatment is highly dependent on early diagnosis and onset of treatment at the earliest time-point possible. Different from other ischemic diseases, however, is the time sensitivity of neuronal cells under ischemic conditions. Recent investigations show that about 2,000,000 neurons die every minute during cerebral ischemia without chance of recovery or long-term substitution (3). This number underscores best the need for early diagnosis and, more so, treatment at the earliest time point possible.

The today's armoury of acute stroke treatment options, however, is alarmingly poor and offers currently not more than one lytic drug and a few newly developed intravascular techniques to remove vessel occluding blood clots. The drug is well known as tissue Plasminogen Activator (tPA), it is approved by the U.S. Food and Drug Administration (FDA) and defines the current gold standard for stroke therapy. Besides its potential benefit, the administration of tPA is restricted, for example, by a required cranial Computed Tomography (cCT) to exclude a pre-existing hemorrhage or the limited treatment window of 4 hours between symptom onset and initiation of the treatment. These and other reasons lead to the fact that not more than 3% of all stroke victims actually receive tPA. Beyond, of those patients who did receive tPA, only about 30% do show a significantly improved clinical outcome on the long-term. Neurointerventional procedures to retrieve the brain vessel occluding thrombus are very promising (5-8) and might achieve future success rates equivalent or close to the ones known from cardiointervention. Downside is that these innovative procedures are restricted to highly specialized medical centers in industrialized countries and they are costly. In contrast, 85% of the world's population lives in low or middle-income countries with limited access or availability of appropriate medical care and in which 85% of deadly strokes occur.

For more information, visit:
››› http://bit.ly/burldevice

Although "time is brain", it is noteworthy that all known or currently developed strategies to tackle stroke take place in the hospital. With regard to existing emergency medicine services (EMS), time is the only ally. Successful stroke diagnosis and treatment becomes a race against the clock. Patient transport times of 10 minutes between first patient contact and hospital admission are common in well-covered metropolitan areas (9). This time window is significantly increased in suburban or rural areas where EMS coverage is limited and transport times of up to several hours are not unusual.

Transcranial ultrasound and microbubbles

Transcranial duplex ultrasound is a non-invasive imaging technique for examination of the central nervous system (CNS) with ultrasound (10). Since the introduction of this technique by Bogdahn et al. in 1990 (10), the method has been proven to be a valid bedside tool for vascular and parenchymal imaging of the brain (11, 12). However, significant limitations of transcranial duplex ultrasound have been: low reproducibility, inter-investigator variability and often unfavorable acoustic bone windows with poor signal-to-noise ratio (13, 14). Signal absorption and reflection at different bone components, like the trabecular and compact bone layers, account for a loss of ultrasound energy of up to 90% (15). Technical development with regard to innovative transducer technologies and advanced computational capabilities increased the transcranial image quality significantly over the last couple of years.

The introduction of transpulmonary stable ultrasound contrast agents (UCA), so called microbubbles, beginning in the early 90's improved the color-coded image quality significantly. This was an important step to overcome an insufficient signal-to-noise ratio for transtemporal as well as transforaminal examinations (16). The evaluation of the intracranial macrovasculature, mainly of the Circle of Willis, achieved clinical relevance with contrast-enhanced transcranial duplex ultrasound, especially in the early diagnosis of acute ischemic stroke (17-19).

The increasing knowledge about the acoustic properties of UCA microbubbles led to new imaging opportunities. Non-linear scattering behavior in the ultrasound field yielded new imaging techniques like harmonic imaging (HI). Harmonic frequencies, which are UCA specific, can be separated from the fundamental frequency and can be used for image generation. Based on these specific acoustic properties, microbubble-specific imaging methods have been developed and enabling, for example, the visualization of the intracranial vasculature in a MR-angiography-like fashion (20).

Microbubbles are primarily designed for diagnostic purposes to enhance the image quality (21, 22). Microbubbles are spheres with an average diameter of 2-3µm. The shell structure is commonly either a phospholipid or human albumin, whereas the inside of the sphere is filled with a perfluorcarbon gas. The agents are administered via a peripheral vein and they are stabilized to pass the lungs to enter the arterial circulation. The half-life of these agents is within the minutes range. Once a microbubble passes an ultrasound field, it undergoes frequent pressure changes, leading to either bubble oscillation (stable cavitation) or bubble destruction (inertial cavitation). Once microbubbles degrade, the gaseous content will be exhaled and the shell structures will be metabolized either in the liver or the spleen.

The International Prehospital Stroke Project (IPSP)

To investigate whether acute ischemic stroke can be detected already in the field, the International Prehospital Stroke Project (IPSP) has been initiated in late 2008. Current active study sites are the University of California, San Diego/USA, and the University of Regensburg/Germany. The project is divided into three main parts. Part I, which was performed in Bavaria/Germany, aimed for the proof of concept that portable transcranial duplex ultrasound can be used either at the site of the emergency or during patient transport by ambulance or helicopter (see Fig. 1) to visualize intracranial vessels in real time (23).

In this study, the average time between arrival at the patient's site and performance of the transcranial ultrasound study was 12min. The study protocol required the primary patient evaluation by the paramedics and the stabilization of the vital signs. The bilateral assessment of the MCA took an average 2min. From this first study we have learned that the emergency assessment of intracranial arteries using portable duplex ultrasound devices is feasible shortly after arrival at the patient's site. Part II aimed for the field diagnosis of acute vessel occlusion using transcranial duplex ultrasound, without or in combination with ultrasound microbubbles. This part is currently ongoing, first results have been published recently (24), showing that main MCA occlusions can be detected with high sensitivity and specificity already at the site of the emergency or during patient transport. The added use of contrast agent microbubbles was beneficial when there was a) an insufficient temporal bone window, it was also useful b) to shorten examination time, c) to increase diagnostic confidence, or d) during difficult examinations. Part III will aim for the potential treatment initiation in the field using transcranial ultrasound in combination with ultrasound microbubbles. A concept has been suggested

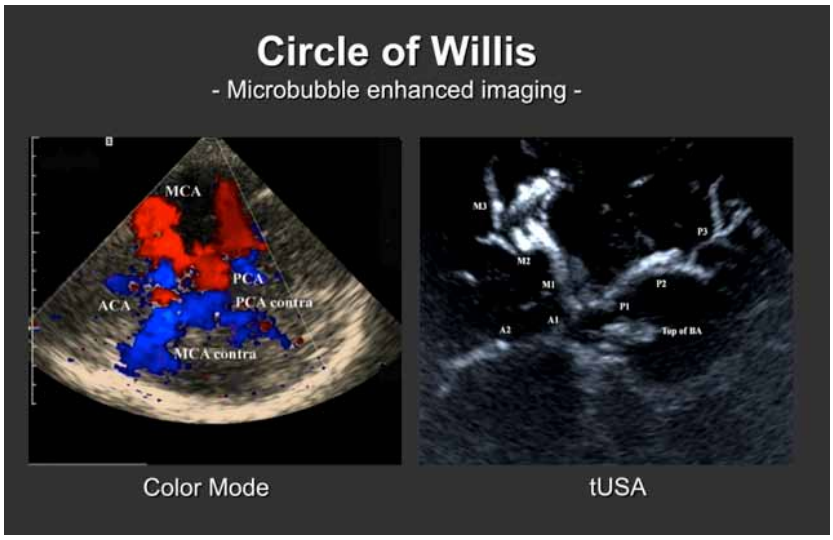

Fig. 2: Transcranial duplex ultrasound, axial scanning view (Visualization of the Circle of Willis, CW, after intravenous injection of ultrasound microbubbles. Left Image: display of CW in standard Color Doppler Mode; red represents blood flow towards the ultrasound probe, blue represents blood flow away from the ultrasound probe. MCA: middle cerebral artery, PCA: posterior cerebral artery, ACA: anterior cerebral artery. Right Image: Same image plane, display of CW using a microbubble specific imaging mode, transcranial Ultrasound Angiography, tUSA)

Fig. 3: Transcranial duplex ultrasound assessment in the helicopter prior to airborne patient transport (Photograph: ???)

recently of how a future prehospital stroke treatment initiation using a dedicated device might look like (see link at the margin).

Prehospital Brain Ultrasound – From Concept to Practice

Training Program for EMS Personnel ➜ Based on the promising results of Part I and Part II of the IPSP, one of the project's aims is to introduce the technology of prehospital transcranial duplex ultrasound to all EMS professionals who do have first contact with a potential stroke victim. The success of prehospital stroke care will depend on the skills of paramedics, EMTs and emergency physicians to perform a transcranial ultrasound study at the site of the emergency or during transport to the hospital. To accomplish this, a first transcranial ultrasound training program for paramedics has been initiated recently. In early May 2012, 45 paramedics of the San Diego Fire Department participated in a single day transcranial ultrasound course, which took place at the University of California, San Diego.

The program included an introduction into the overall concept of prehospital stroke care and the use of portable ultrasound in this context, technical education in device technology and anatomy and extended hands-on sessions. Goal of this first course was to identify the ipsilateral MCA from both sides, to perform flow measurements in the visualized vessel and to evaluate in each individual case, based on predefined image criteria, whether a diagnostic useful information can be assessed without the use of ultrasound microbubbles. The MCA was chosen as the target vessel because about 80% of all ischemic strokes occur in the MCA supply area. Plan is to continue the training program and to offer it to the community.

Portable Transcranial Ultrasound and Wireless Technology ➜ A reasonable approach to significantly improve prehospital stroke care would be the immediate case evaluation by a stroke expert in a remote fashion. Throughout the last years, several stroke telemedicine projects have demonstrated with great success that stroke expertise can be accessed even in rural areas using telecommunication (25-27). Similar to this, a project has been initiated recently at the University of California, San Diego (UCSD) to build in wireless capability into a portable duplex ultrasound device and to send image/video data instantaneously from the device to a certified stroke center for real-time evaluation during patient transport. In collaboration with Philips Medical Solutions a portable, high-end duplex ultrasound device has been modified using 4G-bandwidth for wireless data transfer. To date, the technical feasibility to send image/video data within seconds and over short (urban district) or long (West Coast to East Coast of the USA) distances has been shown. Recently, an according research project has been funded and the study protocol has been approved by the UCSD ethic's committee. Approximate start date of this project is August 2012.

Fig. 4: The initiation of stroke treatment already in the prehospital scenario would potentiate the use of prehospital transcranial ultrasound far beyond its diagnostic capabilities (Photograph: AAMS/Mark Mennie)

Summary

Amongst all medical professionals there is common agreement that stroke is a devastating disease. Stroke has a significant socio-economic impact on stroke victims as well as society. Despite the fact that stroke is one of the most time sensitive diseases, there is currently no compelling concept – diagnostically as well as therapeutically – to provide stroke care already at the earliest time possible, which is at the site of the emergency or during patient transport to the admitting hospital. The use of prehospital transcranial ultrasound to diagnose embolic strokes, performed by trained EMS personnel, which includes physicians, paramedics or EMTs and using wireless technology for remote diagnostic evaluation by stroke and ultrasound specialists, could significantly improve stroke care and therefore decrease the socio-economic burden. The initiation of stroke treatment already in the prehospital scenario would potentiate the use of prehospital transcranial ultrasound far beyond its diagnostic capabilities. The concept of prehospital stroke diagnosis and potential pre treatment, however, should be seen in addition, not competition to existing and established paradigms of stroke care.

References:

1. Donnan GA, Fisher M, Macleod M, Davis SM (2008) Stroke. Lancet 371(9624): 1612-23
2. Mukherjee D, Patil CG (2011) Epidemiology and the global burden of stroke. World Neurosurg 76(6 Suppl): 85-90
3. Saver JL (2006) Time is brain – quantified. Stroke 37(1): 263-6
4. Zivin JA (2009) Acute stroke therapy with tissue plasminogen activator (tPA) since it was approved by the U.S. Food and Drug Administration (FDA). Ann Neurol 66(1): 6-10
5. Broussalis E, Trinka E, Hitzl W et al. (2012) Comparison of Stent-Retriever Devices versus the Merci Retriever for Endovascular Treatment of Acute Stroke. Am J Neuroradiol. EPub DOI: 10.3174/ajnr.A3202.
6. Noorian AR, Gupta R, Nogueira RG (2012) Acute stroke: techniques and results with the Merci retriever. Tech Vasc Interv Radiol 15(1): 47-52
7. Dorn F, Stehle S, Lockau H et al. (2012??) Endovascular Treatment of Acute Intracerebral Artery Occlusions with the Solitaire Stent: Single-Centre Experience with 108 Recanalization Procedures. Cerebrovasc Dis 34(1): 70-7
8. Soize S, Kadziolka K, Estrade L et al. (2012) Mechanical Thrombectomy in Acute Stroke: Prospective Pilot Trial of the Solitaire FR Device while Under Conscious Sedation. AJNR Am J Neuroradiol Seiten ????
9. Evenson KR, Schroeder EB, Legare TB (2001) A comparison of emergency medical services times for stroke and myocardial infarction. Prehosp Emerg Care 5(4): 335-9
10. Bogdahn U, Becker G, Winkler J (1990) Transcranial color-coded real-time sonography in adults. Stroke 21(12): 1680-8
11. Becker G, Lindner A, Bogdahn U (1993) Imaging of the vertebrobasilar system by transcranial color-coded real-time sonography. J Ultrasound Med 12(7): 395-401
12. Schoning M, Staab M, Walter J (1993) Transcranial color duplex sonography in childhood and adolescence. Age dependence of flow velocities and waveform parameters. Stroke 24(9): 1305-9
13. Becker G, Winkler J, Bogdahn U (1991) [Transcranial color-coded real-time sonography in the adult. 1: Normal findings and cerebrovascular ischemia]. Ultraschall Med 12(2): 74-9
14. Becker G, Griewing B (1998) Examination techniques. In: Bogdahn U, Becker G, Schlachetzki F (eds.) Echoenhancers and Transcranial Color Duplex Sonography. 1st ed., Berlin, Blackwell: 219-32
15. Becker G (1998) Artifacts. In: Bogdahn U, Becker G, Schlachetzki F (eds.) Echoenhancers and Transcranial Color Duplex Sonography. 1st ed., Blackwell, Berlin: 112-21
16. Bogdahn U, Becker G, Schlief R et al. (1993) Contrast-enhanced transcranial color-coded real-time sonography. Results of a phase-two study. Stroke 24(5): 676-84
17. Goertler M, Kross R, Baeumer M et al. (1998) Diagnostic impact and prognostic relevance of early contrast-enhanced transcranial color-coded duplex sonography in acute stroke. Stroke 29(5): 955-62
18. Postert T, Federlein J, Braun B et al. (1998) Contrast-enhanced transcranial color-coded real-time sonography: a reliable tool for the diagnosis of middle cerebral artery trunk occlusion in patients with insufficient temporal bone window [letter; comment] [see comments]. Stroke 29(5): 1070-3
19. Gerriets T, Postert T, Goertler M et al. (2000) DIAS I: duplex-sonographic assessment of the cerebrovascular status in acute stroke: A useful tool for future stroke trials. Stroke 31(10): 2342-5
20. Holscher T, Wilkening WG, Lyden PD, Mattrey RF (2005) Transcranial ultrasound angiography (T USA): a new approach for contrast specific imaging of intracranial arteries. Ultrasound Med Biol 31(8): 1001-6
21. de Jong N, Bouakaz A, Frinking P (2002) Basic acoustic properties of microbubbles. Echocardiography 19(3): 229-40
22. Forsberg F, Merton DA, Liu JB et al. (1998) Clinical applications of ultrasound contrast agents. Ultrasonics 36(1-5): 695-701
23. Holscher T, Schlachetzki F, Zimmermann M et al. (2008) Transcranial Ultrasound from Diagnosis to Early Stroke Treatment. 1. Feasibility of Prehospital Cerebrovascular Assessment. Cerebrovasc Dis 26(6): 659-63
24. Schlachetzki F, Herzberg M, Holscher T, et al. (2012) Transcranial ultrasound from diagnosis to early stroke treatment: part 2: prehospital neurosonography in patients with acute stroke: the Regensburg stroke mobile project. Cerebrovasc Dis 33(3): 262-71
25. Audebert HJ, Kukla C, Clarmann von Claranau S et al. (2005) Telemedicine for safe and extended use of thrombolysis in stroke: the Telemedic Pilot Project for Integrative Stroke Care (TEMPiS) in Bavaria. Stroke 36(2): 287-91
26. Ickenstein GW, Horn M, Schenkel J et al. (2005) The use of telemedicine in combination with a new stroke-code-box significantly increases t-PA use in rural communities. Neurocrit Care 3(1): 27-32
27. Schwab S, Vatankhah B, Kukla C et al. (2007) Long-term outcome after thrombolysis in telemedical stroke care. Neurology 69(9): 898-903